

Interventional Therapy of Late Onset Tracheal Stenosis After Implantation of ¹²⁵Iodine Seed Esophageal Stent

Yong-Zhen Wang^{a*}, Yan-Hua Wang^b, Shao-Tong Lai^c, Feng Dai^a, Hai-Feng Xu^d, Hui Chen^d, Ren-Jie Yang^d

^aDepartment of Interventional Radiology and Vascular Surgery, Nanjing Second Hospital, Nanjing University of Chinese medicine, Nanjing, 210003, China.

^bDepartment of Ultrasound, Nanjing Second Hospital, Nanjing University of Chinese medicine, Nanjing, 210003, China.

^cDepartment of The digestion, Rugao BoAi hospital, Nantong, China.

^dDepartment of interventional therapy, Beijing Cancer Hospital, Peking University, Beijing, China.

Abstract

This study reported a case of late-staged esophageal carcinoma, complicated by severe dysphagia late onset tracheal stenosis after treating with ¹²⁵Iodine seed stent implantation. The patient had progressive stenosis of the lower segment (left main trachea) at 6, 26, and 47 days postoperatively. The cause of stenosis might be related to direct press by stent, tumor proliferation, the aortic arch with violate pulsate and the complications caused by other therapies. Due to its short clinical utilization, ¹²⁵Iodine seed stent may present some fatal complications. Therefore, the long-term efficacy of ¹²⁵Iodine seed stent remains to be studied.

Keywords: ¹²⁵Iodine seed; esophagus stent; late onset; tracheal stenosis; complication

INTRODUCTION

Self-expandable metal stent has been extended to apply to advanced and late-staged esophageal cancer, with the safety and therapeutic efficiency of stent loaded with ¹²⁵Iodine seeds confirmed [1, 2]. The occurrence and condition of complication resemble the conventional stent, however, the late onset tracheal stenosis has been rarely reported. This paper reviewed 1 case of late-staged esophageal carcinoma, complicated with late onset tracheal stenosis and severe dysphagia, which had been treated with ¹²⁵Iodine seed stent implantation.

Cases

Female patient, 64 years old. She was diagnosed as esophageal carcinoma in February, 2008. Pathology test categorized as squamous carcinoma (Fig. 1). In operation, it was found that tumor tissue adhered extendedly with intra-meditational main vascular, caused the unreality to remove and application of alternative of radiotherapy (64 Gy/32f in total) combined with 4 periods of adjuvant chemotherapy (TP formula: Docetaxel + Nedaplatin).

The tumor shrunk and symptoms alleviated temporarily, till the dysphagia reoccurred and aggravated at the beginning of June, 2009. The patient then can only be fed with fluid. Combinatorial testing with barium swallows and tracheogram, gastroscopy and CT, it was diagnosed as "esophageal carcinoma stage III, severe esophageal stenosis and Stooler stage 3". The patient was implanted with ¹²⁵Iodine seed stent on August 1st, 2009. The stent was membrane-bundled knitting type, of upper cup, size: 20 mm X 10 cm, produced by Nanjing Weichuang Medical Technology Co., Ltd., Nanjing, China; ¹²⁵Iodine seeds, 0.8mci X 24, produced by Xinke Pharmaceutical Co., Ltd., Shanghai, China. The implantation operation performed smoothly, and hardened lesion and severe stenosis were observed during operation. Post-implantation radiography image indicated the proper stent placing, but with poor stretch. The narrowest section measures as approximately 8 mm (Fig. 2). From the reviewing check by DR (direct digital X-ray) and CT on day 1 (Fig. 3), day 3 (Fig. 4) and day 6 (Fig. 5) after the operation, we can see that the stent has arrived fully extension, with no indication of suppression of surrounding organs (typically the trachea and bronchus). The patient had good appetite and experienced no difficulty in breathing. However, on August 27, 2009 (day 26 post-operation), the patient began suffering from aggravating breath difficulty and concomitant left lower lobe infection and incapacity to cough out. CT image shown stenosis occurred in lower segment and bifurcation of trachea. The symptoms ex-

*Corresponding author: Yong-Zhen Wang

Mailing address: Department of Interventional Radiology and Vascular Surgery, Nanjing Second Hospital, Nanjing University of Chinese medicine, No. 1 Zhongfu Road, Gulou District, Nanjing, Jiangsu 210003, China.

E-mail: yongzhenw@163.com

Received: 12 Jan 2019 Accepted: 15 March 2019

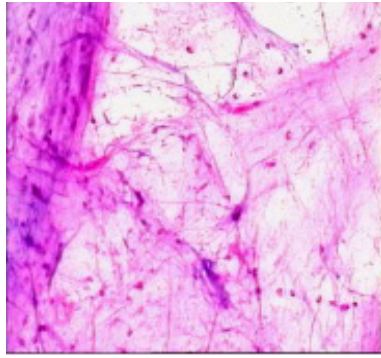


Figure 1. Squamous carcinoma (pathology).

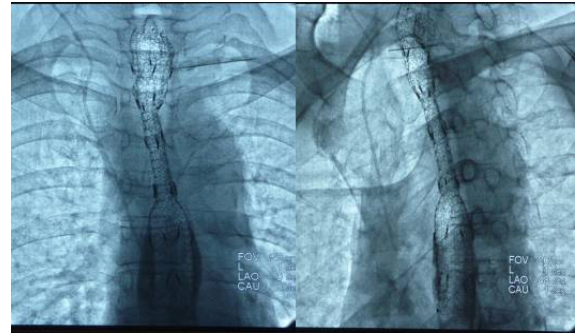


Figure 2. Post-DR image: apparent suppression and stenosis of stent.

acerbated despite of anti- inflammation treatment that patient can not lie on her back (Fig. 6). CT image on September 17, 2009 (day 47 post-operation) demonstrated significant stenosis of lower part and bifurcation of trachea. An “Inverted Y- shaped” stent was performed on the same day (Fig. 8, 9), which contributed to rapid relieve of symptoms. The patient then was able to sleep on her back. One week later, the patient coughed out considerable large volume of yellow purulent sputum and body temperature returned normal. The patient, though lack of appetite, can eat food normally. The patient died of cachexia failure on February 17, 2010 (day 200 post-operation)

DISCUSSION

The radioactive element seed stent was created first by Chinese doctors, which have been applied in clinic successfully for decades. The late onset of tracheal stenosis has been rarely reported [1-4]. The CT images taken on day 6, 26 and 47 post-operation shown progressive stenosis of lower segment (left main trachea). The ¹²⁵Iodine seed is composed of normal membrane-bundled knitting stent, seeds storehouse weaved with alloyed silk thread and radioactive particles. The possible causes for

the late onset tracheal stenosis were analyzed as follows:

1. Direct press by stent: it is often resulted from using over-sized stent or the pressure impacted by “cup” or “ball” on either end of the stent to the posterior wall of the trachea and/or bronchus. Such complication usually released around 1 week after the operation, which can be explained as opening of the cup or fully extension of the stent. Such spatial change can cause pressure to trachea and the posterior wall of bronchus. However, this case cannot be explained by this cause.
2. Tumor proliferation: Continuously growing tumor or lymph node of metastasis directly invades into or suppresses on bronchus. However, the following check by CT confirmed that the tumor shrunk other than expanded after stent implantation, which excludes this cause as well.
3. The aortic arch with violating pulsate, with implantation period increasing, generally affected the tracheal blood circulation, leading to denaturation, putrescence, and cartilage ring collapse, characterized by its late onset.
4. Complications caused by other therapies, especially the radiotherapy (including the external radiotherapy and radioactive particle internal radiotherapy). The ac-

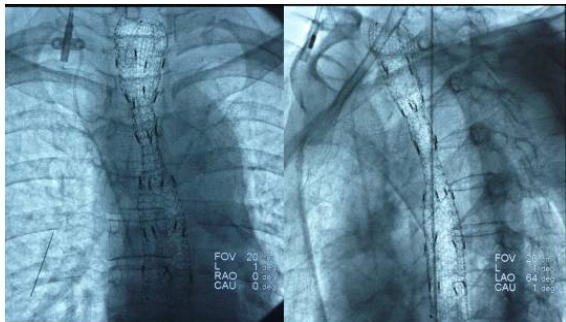


Figure 3. Review on day 1 post-operation. The stent was slightly extended more compared with earlier position.

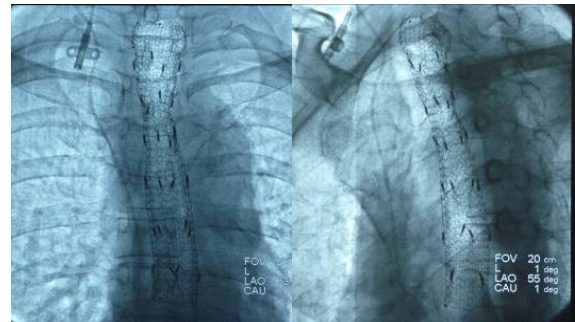


Figure 4. Day 3 post-operation, the stent was nearly fully extended.

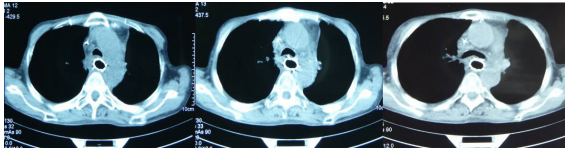


Figure 5. Day 6 post-operation, the stent was fully extended, with no indication of suppression or stenosis to trachea or bronchus.

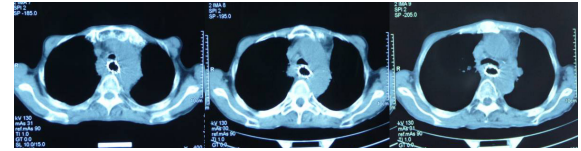


Figure 6. Day 26 post-operation. Slight stenosis observed in bifurcation of trachea.

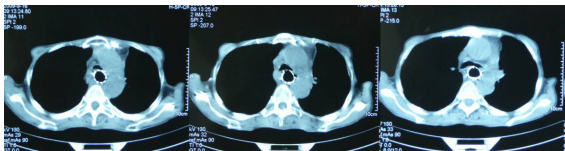


Figure 7. Day 47 post-operation. Apparent stenosis occurred in lower segment, bifurcation and left bronchus.

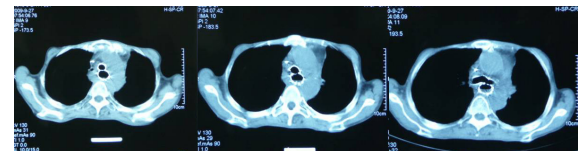


Figure 8. After implantation of "inverted Y-shaped" stent.

cumulating ray may result in tracheomalacia, bronchus collapse, and subsequent stenosis.

Trachea pressure is a severe and lethal complication, which usually occurs after stent implantation for middle esophageal carcinoma of early stage [5-8]. It is frequently caused by mechanical pressure caused by the stent, with position of occurrence consists with the case in this report.

For this reported patient, it was reported of significant collapse on anterior wall of left lower segment of and left main bronchus, approximately the same place of the aortic arch. This position was faced with violate pulsate of the aortic arch and backed against with solid metal stent. Due to the previous radiotherapy against esophageal carcinoma, the accumulated ray effect may have lead to potential trachea damage, which may be worsen by long term continuous exposure to ¹²⁵Iodine seed carried by the stent. The cumulative effect of these factors eventually resulted in the tracheomalacia, trachea collapse, and subsequent stenosis. Judged by the position

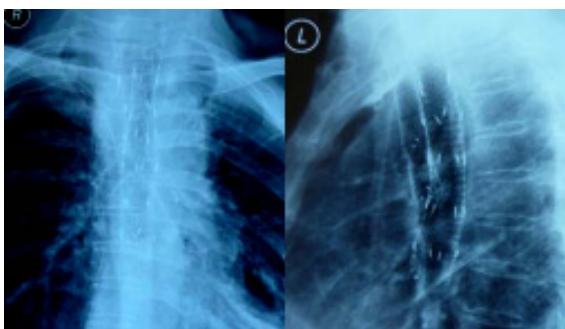


Figure 9. After the implantation of "inverted Y-shaped" stent.

of pathological changes and detailed condition, it was speculated that performing trachea or bronchus stent implantation would alleviate the symptoms of patients. Besides, the complication occurs in the lower segment of left main bronchus, which indicated that "Y-shaped" stent would relieve the stenosis [7,8].

The ¹²⁵Iodine seed stent implantation method, accepted by clinical physicians, exerts radiotherapy to tumor internally produces better anti-tumor effect for the patients with late stage esophageal carcinoma, to raise living standards and prolong survival time. However, its relatively short period of clinical application may involuntary hides some rare but lethal complications from both patients and medical personnel. In summary, the long term effect of ¹²⁵Iodine seed stent remains to be studied.

REFERENCES

1. Guo, J. H., Teng, G. J., Zhu, G. Y., He, S. C., Fang, W., Deng, G., and Li, G. Z. (2008) Self-expandable esophageal stent loaded with 125I seeds: initial experience in patients with advanced esophageal cancer. *Radiology* 247, 574-581
2. Wang, Z. M., Hang, X. B., Cao, J., Hang, G., Chen, K. M., Liu, Y., and Liu, F. J. (2012) Intraluminal radioactive stent compared with covered stent alone for the treatment of malignant esophageal stricture. *Cardiovasc Intervent Radiol* 35, 351-358
3. Zhu, H. D., and Guo, J. H. (2011) Esophageal stent implantation for the treatment of esophageal strictures: its current situation and research progress. *Journal of Interventional Radiology* 20, 494-498
4. Wang, Y. Z., Wang, Y. H., Liu, R. B., He, D. F., and Liu, Y. (2009) Clinical Application of Irradiation Stents in Esophageal and Cardiac Cancer. *China Modern Doctor* 03, 29-30
5. Sharma, P., Kozarek, R., Practice Parameters Committee of American College of, G. (2010) Role of esophageal stents

- in benign and malignant diseases. *Am J Gastroenterol* 105, 258-273;
6. Kujawski, K., Stasiak, M., and Rysz, J. (2012) The evaluation of esophageal stenting complications in palliative treatment of dysphagia related to esophageal cancer. *Med Sci Monit* 18, CR323-329
 7. Han, X. W., Gang, W. U., Gao, X. M., Nan, M. A., and Wang, Y. L. (2005) The clinical practice of inserting two stents in esophagus and trachea. *Journal of Interventional Radiology* 02, 163-166
 8. Lin, A. J., Guo, Q. Y., Liu, Z. Y., and Lu, Z. M. (2010) Double stents indwelling in malignant tracheal and esophageal stenosis. *Biomedical Engineering Clinical Medicine* 03, 240-244